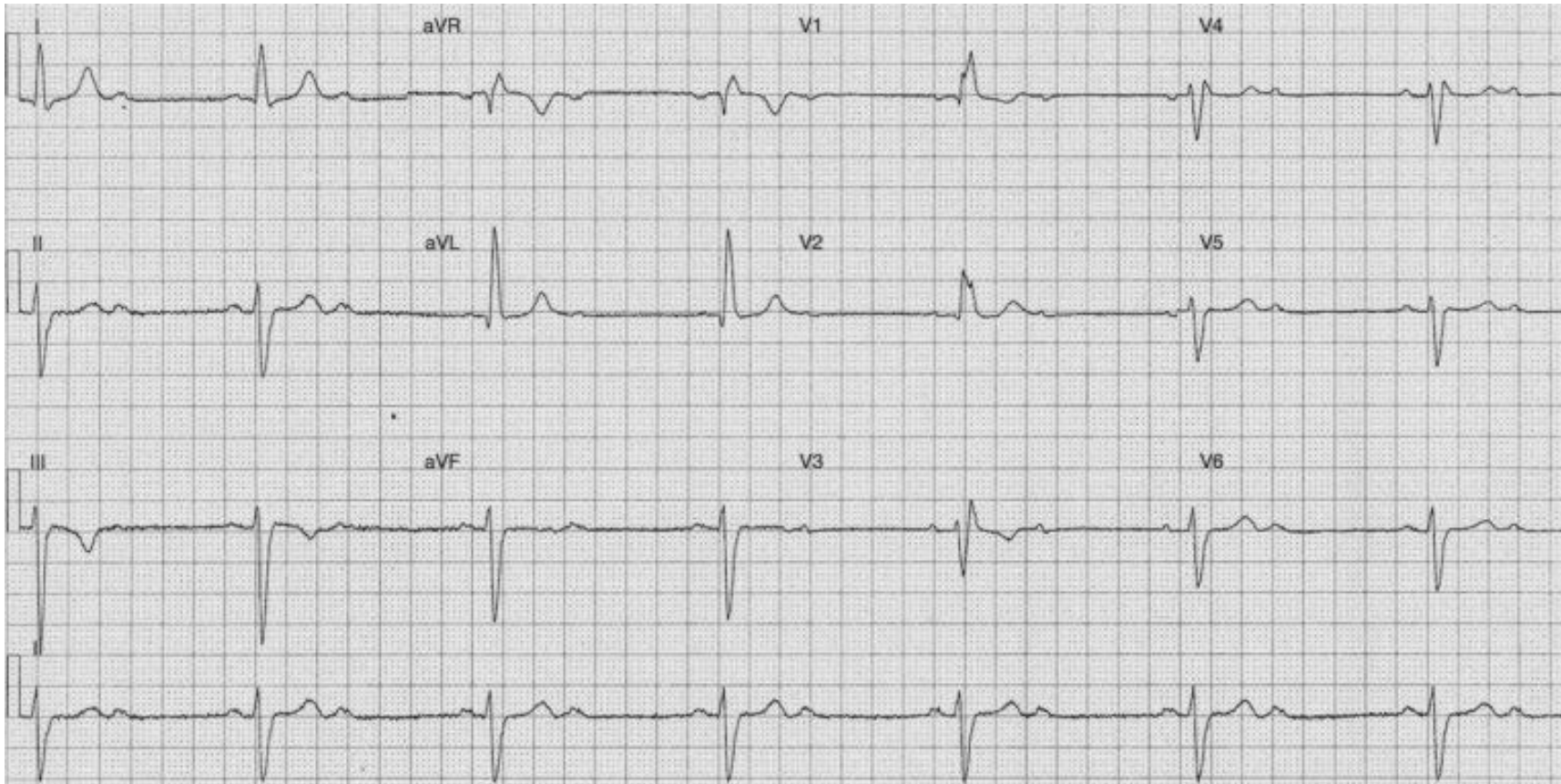


1. 75 year-old male who complaint of dizzy. Past history of HT and DM. BP 125/80mmHg, SpO2: 97 with 2 L O2. 12 Lead ECG done
Please intrepet the following ECG:



Rate: _____

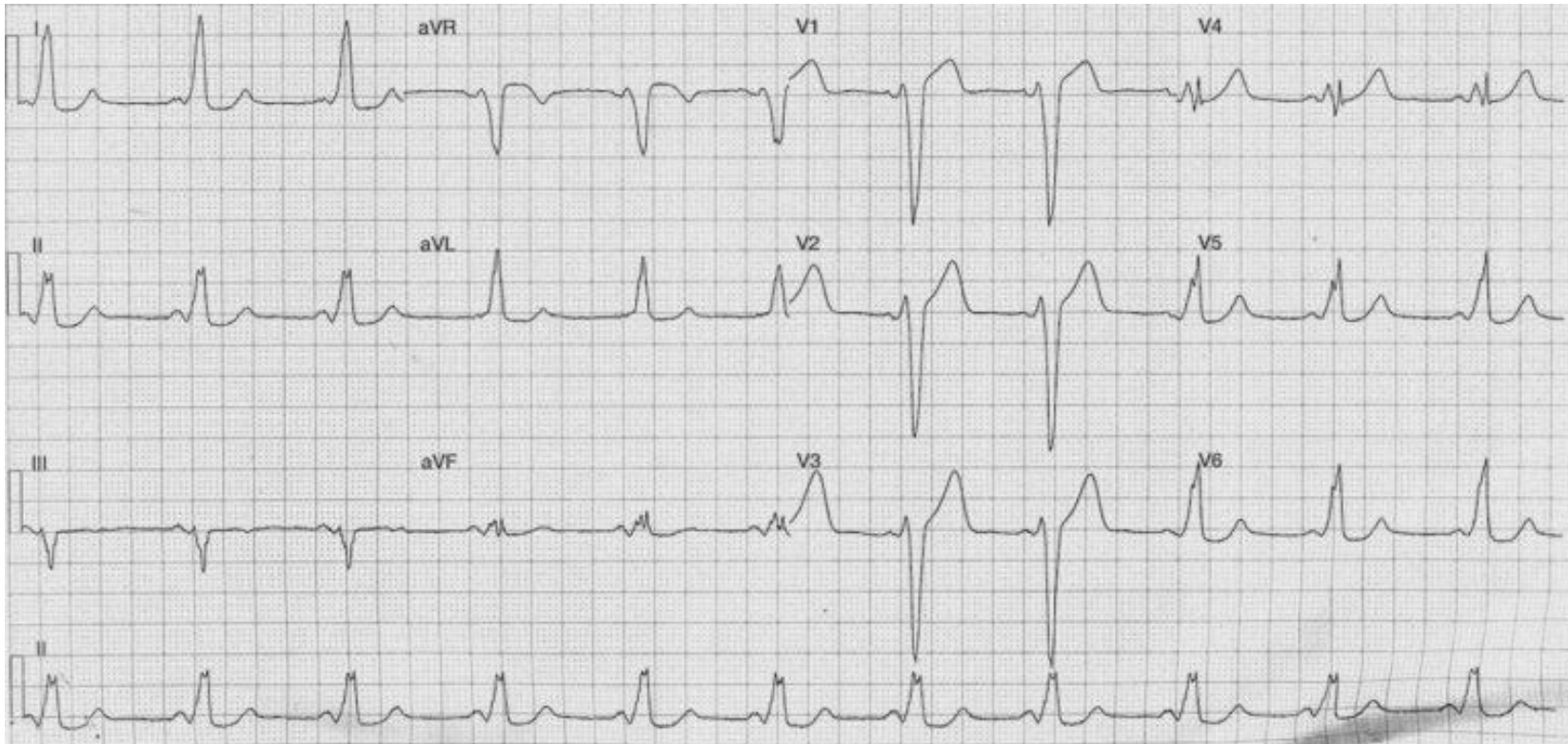
PR interval: _____

QRS complex: _____

T wave: _____

Interpretation: _____

2. 25 year old female attended to A&E because of palpitation. 12 Lead done as below. Please interpretation



Rate: _____

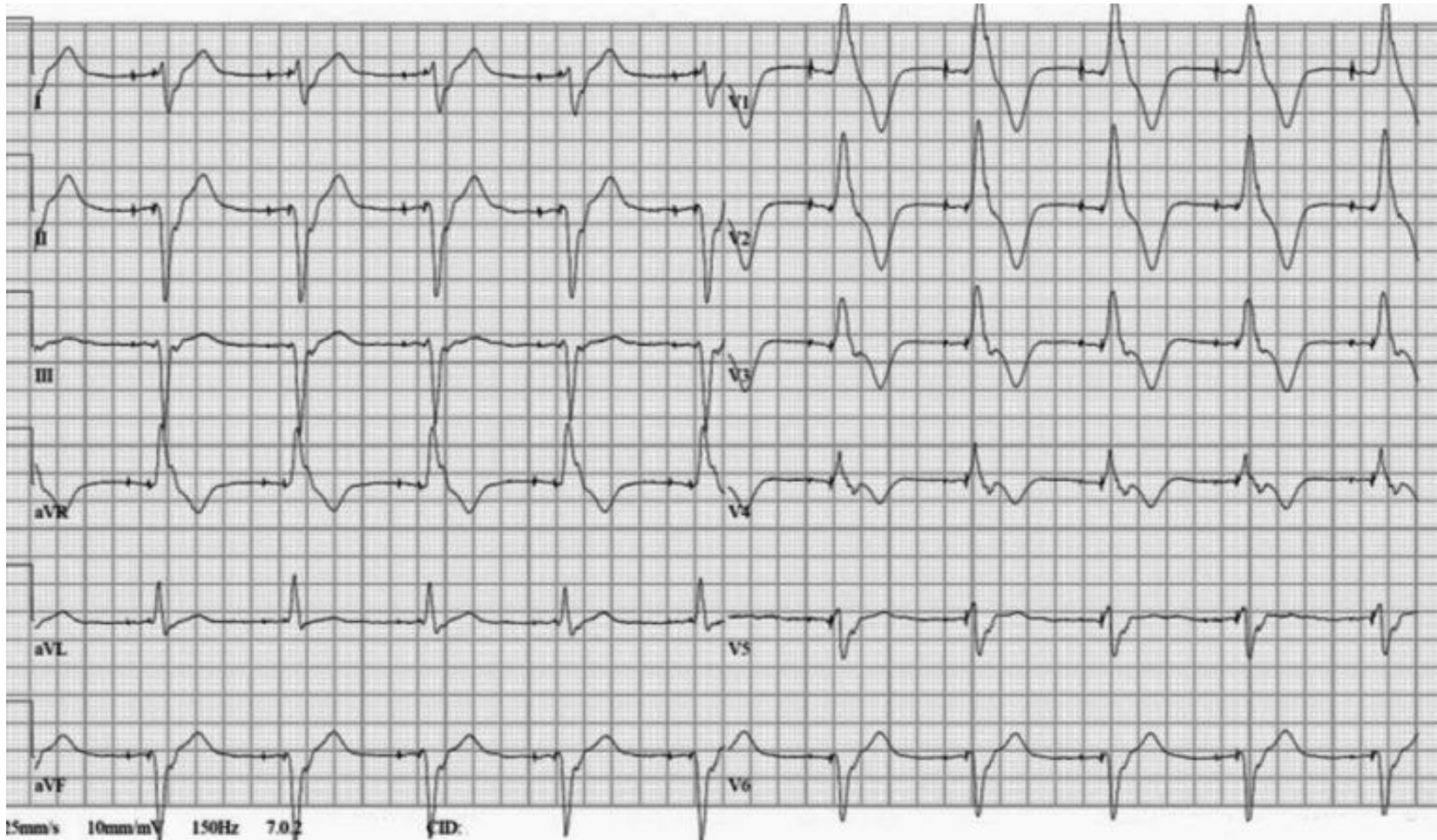
PR interval: _____

QRS complex: _____

T wave: _____

Interpretation: _____

3. 75 year-old male implanted dual chamber permanent pacemaker 3 month ago. He complaint of chest discomfort. Please interpret the below 12 ECG.



Rate: _____

PR interval: _____

QRS complex: _____

T wave: _____

Interpretation: _____